

Superomedial Pedicle Mammoplasty. The Logical Extension Of The Superior Pedicle Technique

Tarek A. Said, Fathy F. Khodair & Sherif Z. Ezzat
Department of Surgery, Cairo University

Abstract

A series of 30 patients of breast hypertrophy were operated upon using the superomedial pedicle technique of reduction Mammoplasty. Nipple elevation up to 14 cms were achieved and resections as large as 3900 gms per breast were done without vascular compromise of the nipple areola complex (NAC viable in 98.3%). Nipple-areola sensation was preserved in 82% of cases and long lasting conical breast projection was always achievable. The superior pedicle technique is recognized by many as a technically easy and capable of producing long lasting aesthetic results. However it is limited to smaller resection. The superomedial pedicle technique is a modification of the superior pedicle technique that retains its inherent advantages but can be applied to larger breasts and allows for more aggressive resection. Incorporation of a medial component to the superior pedicle and lateral rotation of the pedicle instead of self infolding allows for higher elevations of the nipple-areola complex without a significant vascular or sensory compromise. It is an easy, quick and relatively bloodless technique that is suitable to different sizes and types of breast hypertrophy.

The female breast is the strongest feminine character (1). For many women, breast reduction offers a solution for the functional and aesthetic problems associated with large breasts (2).

The search for the ideal technique to reduce the size of large breasts has continued for decades. The objective of a reduction procedure is primarily to reduce the size of the hypertrophic breast with appropriate redraping of the skin envelope while maintaining a viable nipple-areola complex (NAC). Secondary objectives are to provide lasting conical projection, preservation of nipple-areola sensation and minimal scarring (3). The procedure should be quick, relatively bloodless and reproducible with regard to different types and sizes of hypertrophic breasts(4)

Through the 20th century the main controversy centered around the way to transpose the nipple-areola complex to its new higher position. A variety of techniques have been described starting by transposition of NAC as a split thickness skin graft (5). During the last 25 years, the trend has been towards NAC transposition using a variety of combination de-epithelialized dermal and glandular

pedicles. Bipedicle procedures have been proposed horizontally (6)(7) and vertically (8). Single pedicle techniques have been popular using inferiorly (9), superiorly (10)(11), laterally (12) (13), medially (14) and centrally based (15) pedicles.

Bipedicle technique of McKissock (8) & inferior pedicle technique of Robbins (9) received wide acceptance probably because of their reliability regarding nipple areola survival and sensibility on different types of breast (16). However their major criticism has centered around loss of conical projection of the breast due to bottoming out of breast tissue by gravity (17). They are time consuming and require significant technical and artistic energy (18)

The superior pedicle technique was described by Wiener (10) in 1973 to avoid late loss of projection posed with other techniques, the NAC is carried on a superiorly based pedicle taking the whole extent of the medial and lateral skin flaps patterned after Wise (19) as well as the entire new nipple site. This pedicle is folded upwards on itself towards the

which could be fashioned was the major disadvantage of this technique (11) (20)(21) (22). Other complaints include, vascular and sensory compromise of the NAC that can occur with larger pedicles as well as difficulty of infolding of the dermal pedicle(23)

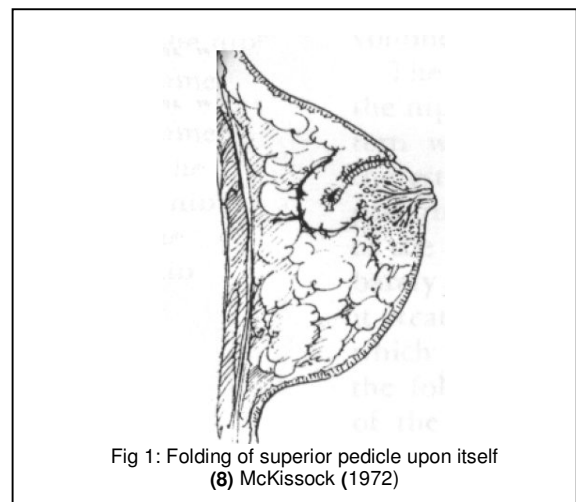


Fig 1: Folding of superior pedicle upon itself
(8) McKissock (1972)

The superomedial pedicle technique was first described by Orlando & Gutherie,(1975) (23) as a modification of the superior pedicle technique. In this technique the NAC is transposed on a superomedial de-epithelialized pedicle which contains a thin layer of subcutaneous tissue to protect the dermal blood supply. This pedicle is based on the full extent of the medial skin flap patterned after Wise (19) and

the entire new nipple position except for a small lateral portion.

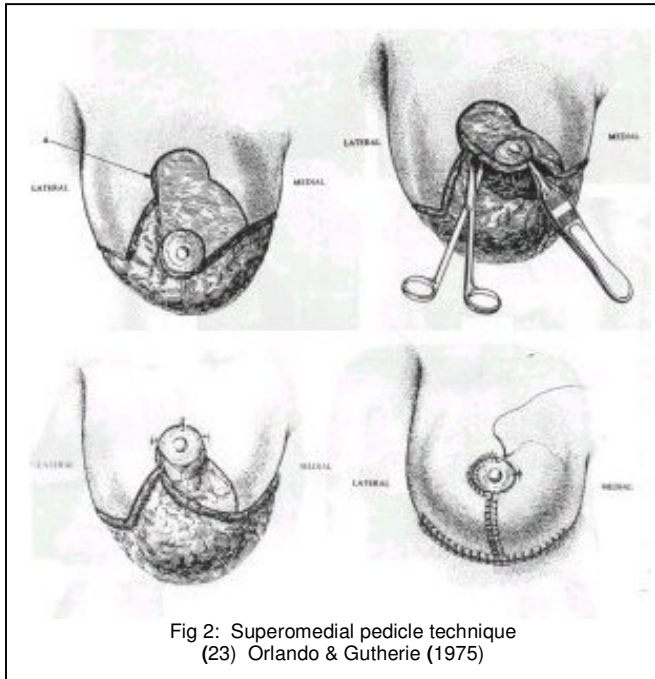


Fig 2: Superomedial pedicle technique
(23) Orlando & Gutherie (1975)

The nipple is laterally rotated into place instead of folding the pedicle upwards in

Hauben (1984) (22) outlined that this technique avoids excessive tension on the transposed NAC produced by the superior pedicle technique and resulting in decrease viability and sensation of the nipple-areola complex. Moreover, it allows for further transposition of NAC than that offered by the superior pedicle technique. According to Hauben, NAC transposition up to 15 cms was possible without vascular compromise of the nipple-areola nor a significant sensory deficit (22)

These two advantages of superomedial over superior pedicle can be explained anatomically:

- 1- The nipple-areola circulation is provided by the internal mammary as well as the lateral thoracic vessels, both of which run in the subcutaneous tissue at a depth of 1-2 cm in the periphery and becomes more superficial as they approach the nipple where branches of both vessels anastomose with each other in a circular fashion around the nipple in the majority of cases. So, by incorporating a medial component to the superior pedicle, additional vascular supply by means of the internal mammary vessels in addition to the lateral
- 2- The nerve supply to the nipple-areola complex comes equally from medial and lateral aspects through anterior and lateral cutaneous branches of the 4th intercostal nerve respectively. Additional nerve supply comes from the anterior cutaneous branches of the 2nd to 5th intercostal nerves and the lateral cutaneous branches of the 3rd to 5th intercostal nerves (24)(25)(26).
- 3- The superomedial base of the pedicle and the lateral rotation of NAC to its new position allows for easy NAC transposition and avoids kinking of the pedicle which occurs with the superior pedicle technique particularly

with larger breasts due to the large size of the pedicle to be folded upwards(22).

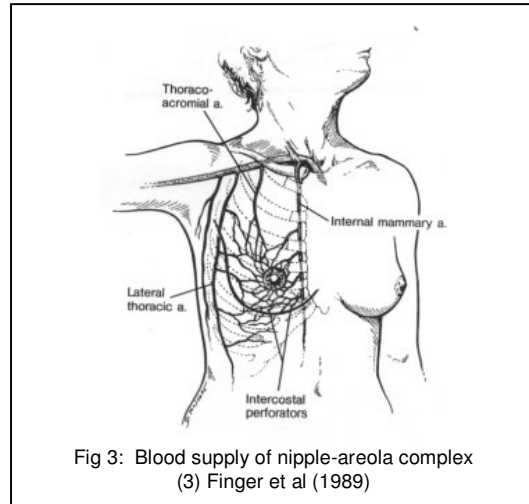


Fig 3: Blood supply of nipple-areola complex
(3) Finger et al (1989)

Patients and methods

30 patients of breast hypertrophy were operated upon using the superomedial pedicle technique in Kasr El-Aini university hospital.

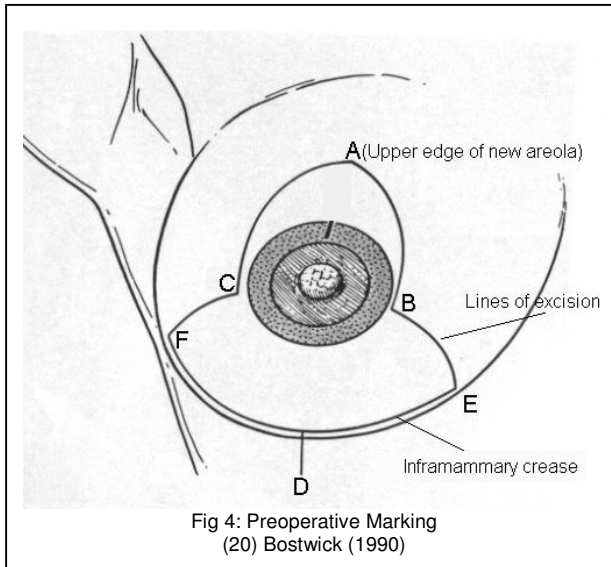
Patient selection

All patients were selected to have moderate to severe breast hypertrophy evaluated by the distance between the suprasternal notch to the nipple (>31 cms).

Preoperative patient marking (Fig: 4)

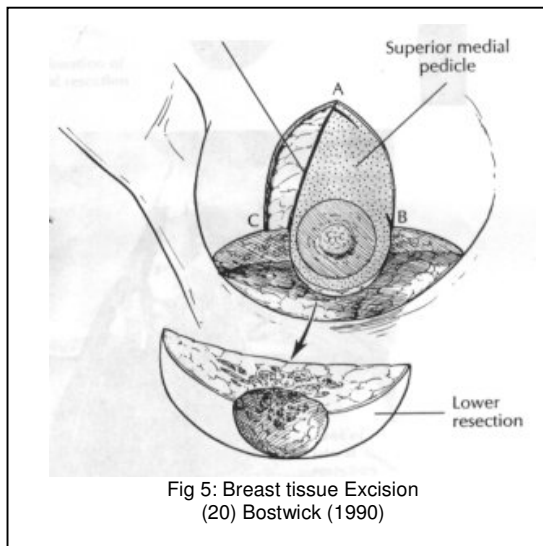
Patient was marked in the sitting position.

- 1-The midline of the breast was marked.
- 2-Then the site of the upper edge of the new areola (Point A) was marked on the breast midline 20-22 cms from the suprasternal notch according to patient height. It was rechecked to coincide with the anterior reflection of the inframammary crease.
- 3-Then an inverted V was drawn from point A, by pushing a small portion of the breast upwards medially and laterally. The arms of the V was initially limited to the width of the areola for conservative skin excision, more skin to be removed at the final stage of the operation
- 4- Then points B & C were marked on the lateral and medial arms of the V to be 9 cms away from Point A (upper edge of the new areola)
- 5-The inframammary fold was marked (starting from the anterior axillary line laterally and stopping medially at the lateral sternal edge).
- 6-Point D was marked at the intersection of midbreast line and the inframammary crease.
- 7-The expected shape of the new breast could be checked by approximating points B and C to point D
- 8- Then the limbs of the V (AB & AC) were joined by straight lines to the respective ends of the inframammary crease (points E & F) to limit the extent of breast resection.
- 9-The new areola was marked by drawing a 4.5 diameter circle within the areola

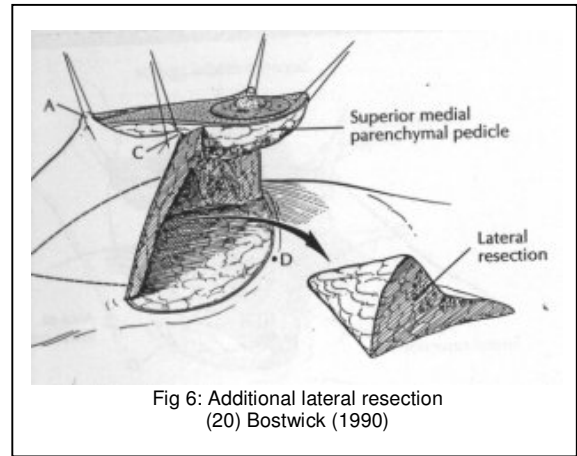


Operative technique

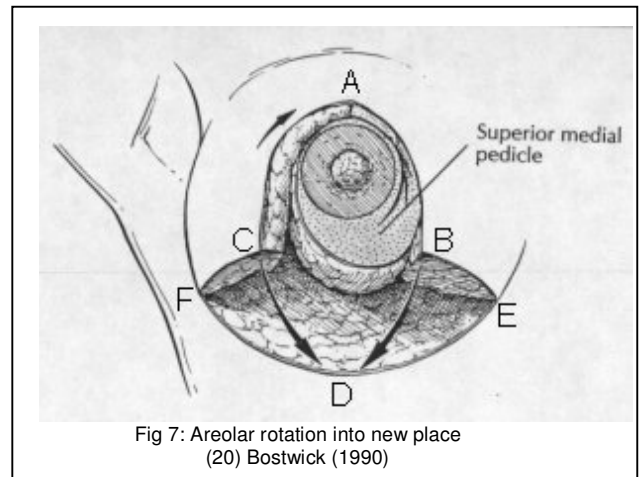
- 1- Infiltration of Xylocaine with 1:200000 Epinephrine in the prepectoral and incisional areas except for the nipple-pedicle region greatly reduced operative blood loss
- 2- The inverted V area was de-epithelialized using sharp scissors including the outer rim of the old areola outside the new areolar marking.
- 3- The inframammary crease incision was deepened till the deep fascia and the breast was lifted off the pectoral fascia up to the nipple-areola level. Perforating branches to breast tissue were coagulated.
- 4- Then the breast was lifted upwards perpendicular to the chest wall and the lower portion of the breast projecting below the final inframammary crease was excised. (Fig 5)



- 5- A wedge of lateral tissue and a tangential disk of deep central tissue were resected (Fig 6)

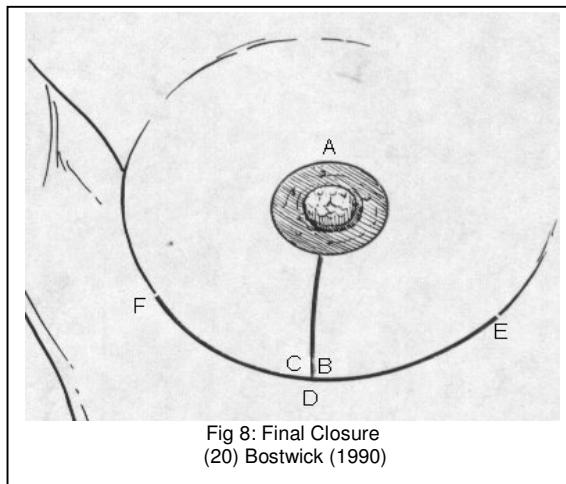


- 6- The nipple areola complex was held by hooks and the superomedial pedicle was undermined at 2 cm thickness and made progressively thicker towards the base.
- 7- The base of the pedicle was widened with larger breasts (Longer pedicles).
- 8- The pedicle was freed laterally by an incision at the lateral edge of the V (AC) all the way upwards till a point
- 9- The nipple and areola were then laterally rotated easily into their new place (Fig 7), With shorter pedicles a small 1-2 cm dermis-only back cut was done upwards at point B to facilitate rotation of pedicle. (fig 5)



- 10- The areolar apex was secured to point A, breasts checked for symmetry in the sitting position.
- 11- Temporary clips were used to approximate points B,C to D and to close the new inframammary crease incision EF and the vertical incision AD. (Fig 7)
- 12- Breasts were rechecked for symmetry, and more skin was removed at this stage to achieve best contour and to avoid any dog ears laterally and medially.
- 13- The proposed areolar position was prepared by drawing a circle 4 cm in diameter starting from point A and the circle of skin was excised in full thickness to accommodate for the transposed areola.
- 14- Effective hemostasis was achieved
- 15- Suction drains were inserted bilaterally.
- 16- Final closure proceeded by 4-0 Vicryl intracuticular sutures of the areola and 4-0 subcutaneous Vicryl

sutures and subcuticular 3-0 Prolene sutures, of lines AD and EF (new inframammary crease) (Fig 8)



- 17- A light dressing was applied
- 18- Drains were removed after 48 hours and stitches removed after 10 days

Results

- 59 breasts in 30 patients were operated upon for breast hypertrophy using the superomedial pedicle technique. (One case was done unilaterally to match the size of a contralateral post-mastectomy reconstructed breast using TRAM flap).
- Age ranged from 18-40 years with a mean age of 24.5 yrs
- Patients were selected to have moderate to severe breast hypertrophy (Nipple-Suprasternal notch distance ranging from 31-37 cms with a mean of 34.7 cms)
- The amount of nipple transposition ranged from 8-14 cms with a mean of 11.7 cms
- The amount of breast tissue excised per breast ranged from 800-3900 gms with a mean of 1300 gms
- Operative time per breast ranged from 55-90 minutes with a mean of 67 minutes.

Complications (Table 1)

	breasts	%
Early Complications		
Dehiscence at T-junction	4	6.8%
Nipple-areola necrosis	1	1.7%
Hematoma	2	3.4%
Cellulitis	2	3.4%
Skin Necrosis		
Late Complications		
Nipple-areola Sensory Loss	10	18%
Under-reduction	2	3.4%
Over-reduction	0	0%
Recurrent Ptosis	0	0%
Scar Hypertrophy	4	6.8%
Nipple Retraction	0	0%
Contour Problems	2	3.4%
Dog Ears	2	3.4%

Table 1: Complications

Early complications were reported in 7 breasts (11.8%) and they were all managed conservatively except for hematomas in 2 breasts which needed surgical evacuation

*Partial nipple and areola necrosis less than 25% of areolar diameter occurred in one breast (1.7%) in the upper outer areolar margin and was treated with repeated dressing . It healed with secondary intention without the need of revision

*Hematoma formation occurred in 2 breast (3.4 %) and were evacuated surgically.

*Wound dehiscence occurred at the T-junction in 4 breasts (6.8 %) and treated conservatively with repeated dressings

*Cellulitis occurred in 2 breasts (3.4 %) and was treated with proper antibiotics.

Late complications

1-Sensory loss

Nipple-areola sensation tested by touch and 2-point discrimination was preserved in 41 breasts (82%)

2-Size

*Bilateral symmetry was achieved in all cases.

*Under-reduction was a complication in one patient (3.4%).

Patient declined to have revisional surgery to correct it

*There was no cases of over reduction

3-Recurrent breast ptosis

Over a 6-month period follow-up no cases showed recurrent breast ptosis

4-Scar hypertrophy was noticed in 4 breasts (6.8%). It affected the vertical and horizontal limbs of the T-junction . Areolar scar escaped hypertrophy in all cases.

5-No cases of nipple retraction were noted over 6 months

6-Lateral dog ears were found in 2 breasts 3.4% and were revised surgically.

7-Contour problems

*Conical projection of the breast was achieved in 29 patients (96.6%) . Conical projection was preserved after 6 months in all cases (100%)

*Boxy appearance of the breast with loss of conical projection was found in one patient (3.4%) and was due to over excision of breast tissue centrally beneath the pedicle .

Discussion

Reduction Mammoplasty techniques differ in the way the nipple-areola complex is transposed to its new higher position. During the past two decades the trend was towards using a combination dermal and glandular pedicle. The bipedicle technique of McKissock(8) and the inferior pedicle technique of Robbins (9) became the mainstay of modern reduction mammoplasty (3). Those two techniques are able to achieve good cosmetic result with a reliable vascular and nerve supply to the nipple-areola complex. However they have the major disadvantage of late loss of conical projection due to sagging of lower breast tissue (17)(18).

The superior pedicle mammoplasty is able to produce a long lasting projection of the breast with good reliability regarding NAC viability and sensibility, however, it has pedicle length limitations that makes the technique unsuitable for larger degrees of breast hypertrophy (23).

Superomedial pedicle technique designed by Orlando & Gutherie (23) was found to combine the advantage of the previous techniques and to offer a reliable solution for their inherent disadvantages.

In a 30-patient series, this technique was able to reduce huge breasts allowing for up to 14-cm nipple elevation

(pedicle length) without vascular compromise to the nipple-areola complex in contrast to superior pedicle technique. Nipple-areola complex was viable in all breasts except one (98.3%). Partial necrosis occurred in less of 25% of the areolar edge in one case and healed conservatively. Sensibility of the nipple-areolar complex was preserved in 82% of cases which matches results obtained by other investigators (3)(22)(23). This is explained by the fact that incorporating a medial component to the superior pedicle preserves the anterior cutaneous branches of the 2-5th intercostals nerves. This technique was able to produce a good aesthetic result as regards conical breast projection in 96.6 % of cases and the result was maintained over a 6 months follow up period. The lateral rotation of the pedicle employed in this technique away from its base prevents undue tension on the nipple-areola complex as well as pedicle kinking in huge breast reductions.

Conclusion

Superomedial pedicle mammoplasty technique appears to a safe, reliable modality, suitable for different sizes and shapes of breast hypertrophy with excellent aesthetic results and a low rate of complications. Long lasting conical breast projection is achievable in all cases and nipple-areola vascularity and sensation are not compromised even with extensive reductions. It has a low rate of early and late complication. The operation is quick and relatively bloodless. It is relatively easy and is suitable for less experienced surgeons and trainees. It appears to be the logic extension of the superior pedicle technique extending its applicability to manage moderate to severe breast hypertrophy.

References

- 1-Bahman Guyuron.** Plastic Surgery. Indications, Operations and Outcomes. Mosby, 2000: 2709
- 2-Claire L.F. Temple & Lawrence N. Hurst.** Reduction mammoplasty improves breast sensibility. Plastic and Reconstructive Surgery, 1999;104(1):72-76.
- 3-Ronald E. Finger, Bernabe Vasquez, Stephenson Drew & Kenna S. Given.** Superomedial pedicle technique of reduction mammoplasty. Plastic and Reconstructive Surgery, 1989;83(3): 471-478
- 4-Ted Lockwood.** Reduction Mammoplasty and mastopexy with superficial fascial system suspension. Plastic and Reconstructive Surgery, 1999;103(5):1411-1420
- 5-Thorek M.** Possibilities in the reconstruction of the human form. NY Med J Rec, 1972;116:572. Cited in Bahman Guyuron, 2000. Plastic Surgery. Indications, Operations and Outcomes. Mosby, 2000: 2709
- 6-Strombeck J.O.** Reduction mammoplasty. A report on a new technique based on the two-pedicle procedure. Br. J. Plast. Surg., 1960;13:79-90
- 7-Pitanguy I.** Surgical treatment of breast hypertrophy. Br. J. Plast. Surg., 1967;20:78
- 8-Paul K. Mckissock.** Reduction mammoplasty. With a vertical dermal flap. Plastic & Reconstructive Surgery, 1972;49(3): 245-252
- 9-Robbins T.H.** A reduction mammoplasty with the nipple-areola based on an inferior dermal pedicle. Plastic & Reconstructive Surgery, 1977;59:64
- 10-Wiener D.L., Aiache A.E., Silver L., and Tittiranonda T.** A single dermal pedicle for nipple transposition in subcutaneous mastectomy, reduction mammoplasty or mastopexy. Plastic & Reconstructive Surgery, 1973;51:115
- 11-Hugo N.E. and McClellan R.H.** Reduction mammoplasty with a single superiorly based pedicle. Plastic & Reconstructive Surgery, 1979;63:230
- 12-Skoog T.** A technique of breast reduction: Transposition of the nipple on a cutaneous vascular pedicle. Acta Chir Scand., 1963 ;126 :453 Cited in Ronald E. Finger, Bernabe Vasquez, Stephenson Drew & Kenna S. Given, 1989. Superomedial pedicle technique of reduction mammoplasty. Plastic and Reconstructive Surgery, 1989;83(3): 471-478
- 13-Camarena & Rafael Vergara.** Reduction mammoplasty with superior-Lateral dermoglandular pedicle: Another Alternative. Plastic & Reconstructive Surgery, 2001;107(3):693-699
- 14-Maurice Y. Nahbedian, Bernard M. McGibbon, & Paul N. Manson.** Medial pedicle reduction Mammoplasty for severe mammary hypertrophy. Plastic and Reconstructive surgery, 2000;105(3):896-904
- 15-Gasperoni C., Salgarello M. & Gasperoni P..** A personal technique: Mammoplasty with J scar. Ann Plast. Surg., 2002;48(2):124-130
- 16-Wechselberger G., Stoss S., Schoeller T., Oehlbauer M. & Piza-Katzer H.** An Analysis of breast sensation following inferior pedicle Mammoplasty and the effect of the volume of resected tissue. Aesthetic Plast. Surg. ,2001;25(6):443-446
- 17-Mizgala C.L., & MacKenize K.M.** Breast reduction outcome study. Ann Plast. Surg., 2000;44(2): 125-133
- 18-Heinz Bohmert & Christina J. Gabka.** Plastic and Reconstructive Surgery of the Breast. A Surgical Atlas. Thieme. Stuttgart. New York, 1997:37

19-Wise R.J. A preliminary report on a method of planning the mammoplasty. *Plastic and Reconstructive Surgery*, 1956;17:356.

20-John Bostwick III. *Plastic and Reconstructive Breast Surgery*. Quality Medical Publishing Inc. St. Louis: Mosby, 1990

21-Georgiade N.G., Serafin D., Riefkohl R., and Georgiade G.S. Is there a reduction mammoplasty Surgery, 1979;63:765.

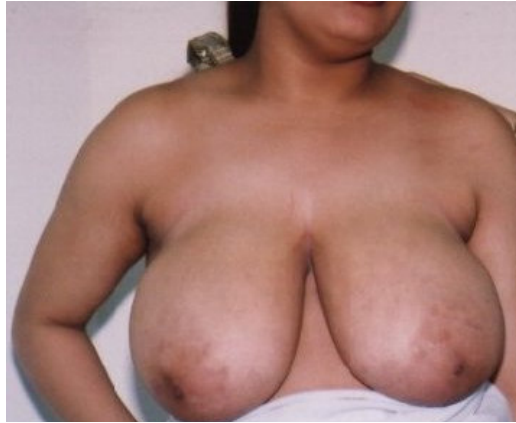22-Hauben D.J. Experience and refinements with the superomedial dermal pedicle for the nipple-areola transposition in reduction mammoplasty. *Aesthetic Plast. Surg.*, 1984;8:189

23-Orlando J.C., and Gutherie R.H. Jr. The superomedial dermal pedicle for nipple transposition. *Br. J. Plast. Surg.*, 1975;28:42-45

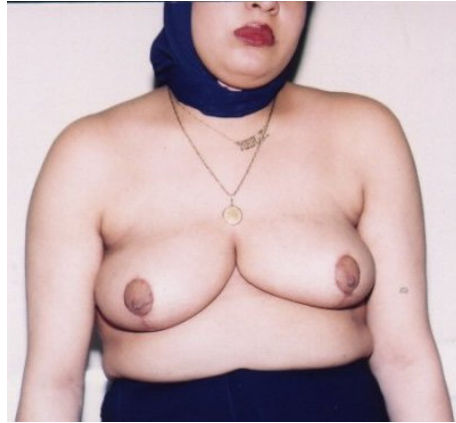24-Muriel Greuse, Moustapha Hamdi, and Albert DeMey. Breast sensitivity after vertical Mammoplasty. *Plastic and Reconstructive Surgery*, 2001;107(4):970-976.

25-Benediktsson K.P., Perbeck L., Geigant E., & Solders G. Touch sensibility in the breast after subcutaneous mastectomy and immediate reconstruction with a prosthesis. *Br. J. Plast. Surg.*, 1997;50: 443-449

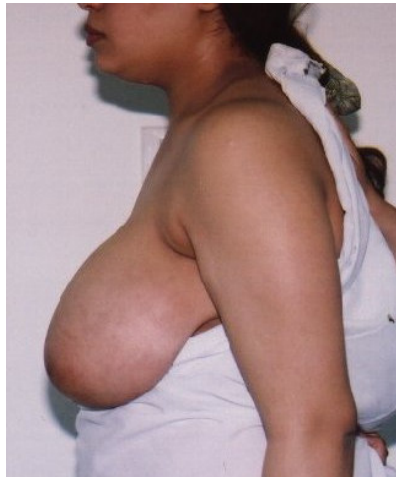26- Jaspars J.J.P., Posma A.N., van Immerseel A.A.H., & Gittenberger-de Groot A.C. The cutaneous innervation of the female breast and nipple-areola complex: Implications for surgery. *Br. J. Plast. Surg.*, 1997;50: 249-259



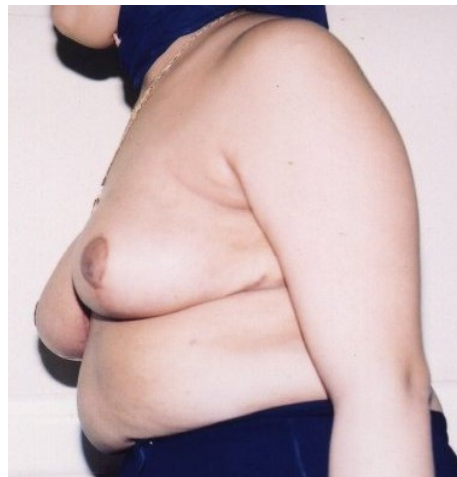1 A



1B



1C



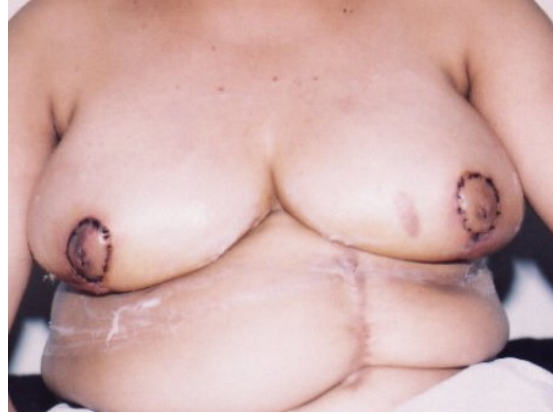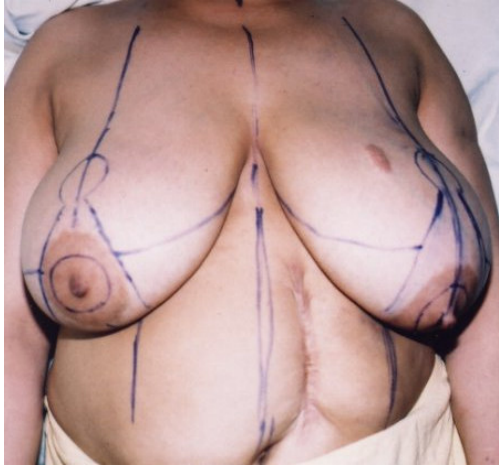1D

Case 1

A: Preoperative Frontal View. B: 6-months Postoperative Frontal View

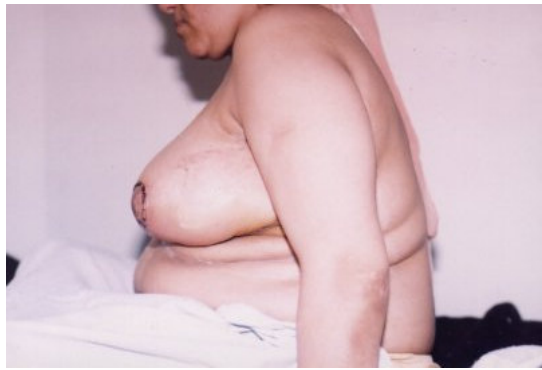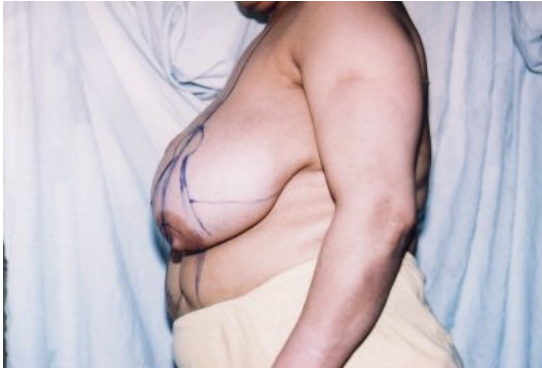C: Preoperative Lateral View. D: 6-months Postoperative Lateral View

A 19-year old patient with huge breast hypertrophy (suprasternal notch to nipple distance 34 cms). Superomedial pedicle technique was used. Nipple was elevated 12 cms with good viability and sensation. Good breast projection was maintained after 6 months.



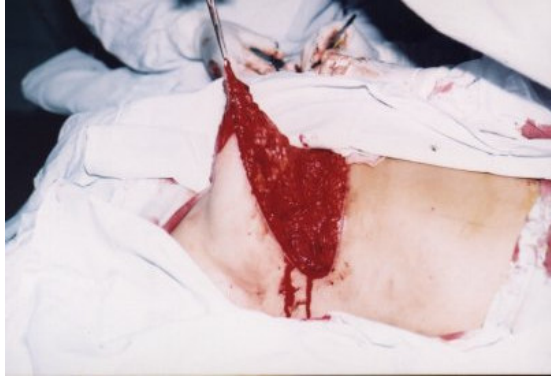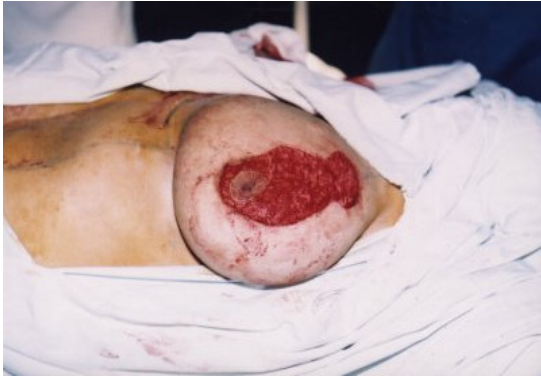2A

2B



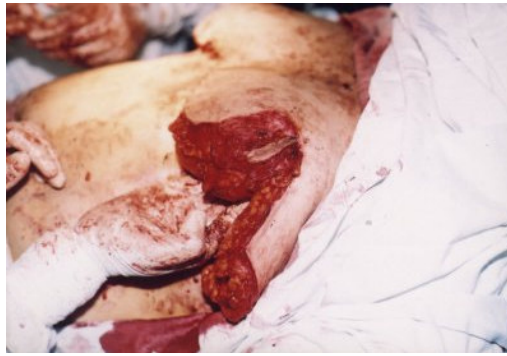2C

2D



2E

2F

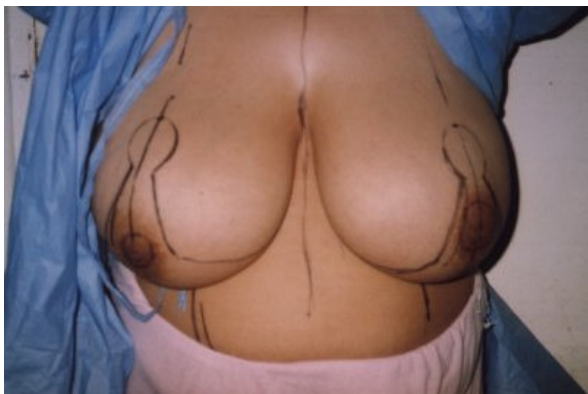

2G

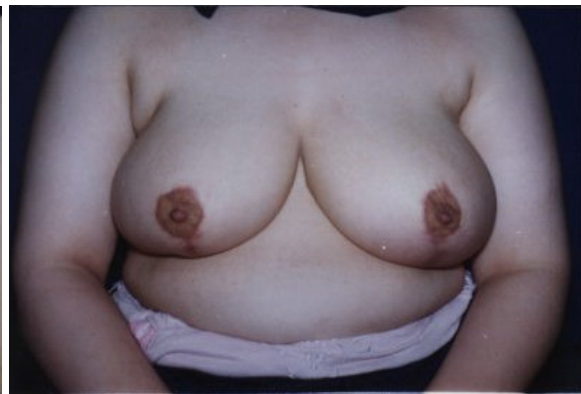Case 2

A: Preoperative Frontal View. B: Early Postoperative Frontal View
 C: Preoperative Lateral View. D: Early Postoperative Lateral View
 E: Intraoperative De-epithelialization of pedicle area. F: Excision of breast tissue
 G: Pedicle rotated laterally and nipple fixed into place

A 38-year old patient with huge breast hypertrophy. Note the discrepancy in nipple direction, level and breast size between both breasts. Suprasternal notch to nipple distance was 37 cms in left breast and 33 cms in the right. Superomedial pedicle technique was used. Nipple was elevated 14 cms in the left breast and 10 cms in the right. Symmetrical nipple level and direction and symmetrical breast size were achieved with good breast projection and good nipple and areola viability and sensibility.



3A



3B

Case 3

A: Preoperative Frontal View. B: 6-months Postoperative Frontal View

A 22-year Old patient with moderate breast hypertrophy. Suprasternal notch to nipple distance was 33 cms in the right breast and 31 cms in the left. Superomedial pedicle mammoplasty was performed elevating right nipple for 10 cms and the left for 8 cms with good viability and sensation. 6 mponth postoperatively, good conical breast projection is maintained.