

Seminar

Hypertensive emergencies

Carl J Vaughan, Norman Delanty

A hypertensive emergency is a situation in which uncontrolled hypertension is associated with acute end-organ damage. Most patients presenting with hypertensive emergency have chronic hypertension, although the disorder can present in previously normotensive individuals, particularly when associated with pre-eclampsia or acute glomerulonephritis. The pathophysiological mechanisms causing acute hypertensive endothelial failure are complex and incompletely understood but probably involve disturbances of the renin-angiotensin-aldosterone system, loss of endogenous vasodilator mechanisms, upregulation of proinflammatory mediators including vascular cell adhesion molecules, and release of local vasoconstrictors such as endothelin 1. Magnetic resonance imaging has demonstrated a characteristic hypertensive posterior leucoencephalopathy syndrome predominantly causing oedema of the white matter of the parietal and occipital lobes; this syndrome is potentially reversible with appropriate prompt treatment. Generally, the therapeutic approach is dictated by the particular presentation and end-organ complications. Parenteral therapy is generally preferred, and strategies include use of sodium nitroprusside, β -blockers, labetalol, or calcium-channel antagonists, magnesium for pre-eclampsia and eclampsia; and short-term parenteral anticonvulsants for seizures associated with encephalopathy. Novel therapies include the peripheral dopamine-receptor agonist, fenoldapam, and may include endothelin-1 antagonists.

A hypertensive emergency is defined as a situation that requires immediate blood-pressure reduction (not necessarily to normal values) to prevent or limit target-organ damage, and a hypertensive urgency is defined as a situation in which blood pressure should be lowered within a few hours.¹ The distinction between emergencies and urgencies is important because it dictates management. Patients with target-organ damage, such as encephalopathy or aortic dissection, require emergency blood-pressure reduction with intensive monitoring and parenteral drug therapy. Patients presenting with significantly raised blood pressure but without evidence of target-organ injury need urgent, but not emergency, blood-pressure reduction. This aim can be achieved by use of oral agents and without intensive-care monitoring.

Epidemiology

About 20–30 % of adults in the more developed countries have hypertension. Blood pressure tends to increase with age in most societies, and hypertension is slightly more common in men than in women, especially in younger and middle-aged groups.² In the USA, the incidence and prevalence of hypertension are about 1.5–2.0 times greater in African Americans than in the white population.³ The exact prevalence of hypertension depends on definition. In general, definite hypertension has been taken to be a blood pressure, on two or more clinic readings, of more than 160/100 mm Hg in the UK and more than 140/90 mm Hg in North America. The advent of ambulatory blood-pressure monitoring has complicated the definition of hypertension, but it may help to define risk further. Guidelines from various organisations^{4,5} have given

somehow varying definitions and recommendations for treatment. Most guidelines for the treatment of hypertension discuss the issue in relation to reduction in the risk of chronic end-organ damage and do not specifically address the prevention of acute hypertensive complications. However, the assumption that improved treatment of chronic hypertension should also lead to a reduction in the incidence of hypertensive emergencies seems reasonable. This hypothesis is supported by data from a 1988 study of 100 patients with severe hypertension (two-thirds of whom had evidence of end-organ damage) admitted to a large urban hospital.⁶ In that series, 93% of patients had previously been diagnosed as having chronic hypertension; this finding suggests that improved management of pre-existing known hypertension could lower the incidence of hypertensive emergencies. Data from the Framingham Heart Study confirm that appropriate, monitored long-term treatment of hypertension lowers the incidence of hypertensive complications.⁷ Unfortunately, the recognition and correct treatment of hypertension in the general population are still not adequate, and many physicians may be complacent about the need for aggressive control of raised blood pressure.^{8–10} Thus, many patients with unrecognised or undertreated hypertension may be at increased risk of the development of hypertensive emergencies, as well as its more insidious consequences.

Pathophysiology

The causes of hypertensive emergencies and urgencies are shown in the panel. Any disorder that causes hypertension can give rise to a hypertensive emergency. The rate of change in blood pressure determines the likelihood that an acute hypertensive syndrome will develop.¹¹ Pre-existing chronic hypertension may lower the probability of a hypertensive emergency (at a particular blood pressure) through adaptive vascular changes that protect end organs from acute changes in blood pressure. Conversely, in patients without pre-existing chronic hypertension (eg, those who have become hypertensive in the setting of acute glomerulonephritis or pre-eclampsia) a hypertensive emergency can develop at substantially lower blood pressures.¹¹

Lancet 2000; **356**: 411–17

Division of Cardiology, Department of Medicine, Weill Medical College of Cornell University, New York Presbyterian Hospital, New York, NY, USA (C J Vaughan MRCP); and Department of Clinical Neurological Sciences, Royal College of Surgeons in Ireland, and Division of Neurology, Beaumont Hospital, Dublin 9, Ireland (N Delanty MRCP)

Correspondence to: Dr Norman Delanty (e-mail: norman.delanty@eircom.net)

Causes of hypertensive emergencies

Essential hypertension
 Renal parenchymal disease
 Acute glomerulonephritis
 Vasculitis
 Haemolytic uraemic syndrome
 Thrombotic thrombocytopenic purpura
 Renovascular disease
 Renal-artery stenosis (atheromatous or fibromuscular dysplasia)
 Pregnancy
 Eclampsia
 Endocrine
 Pheochromocytoma
 Cushing's syndrome
 Renin-secreting tumours
 Mineralocorticoid hypertension (rarely causes hypertensive emergencies)
 Drugs
 Cocaine, sympathomimetics, erythropoietin, cyclosporin, antihypertensive withdrawal
 Interactions with monoamine-oxidase inhibitors (tyramine), amphetamines, lead intoxication
 Autonomic hyper-reactivity
 Guillain-Barré syndrome, acute intermittent porphyria
 Central-nervous-system disorders
 Head injury, cerebral infarction/haemorrhage, brain tumours

The endothelium has a central role in blood-pressure homeostasis by secreting substances such as nitric oxide and prostacyclin, which modulate vascular tone through vasodilation (figure 1).¹² Nitric oxide is released under the influence of endothelial agonists such as acetylcholine, norepinephrine, and substance P. It is also released by the endothelium in response to mechanical forces such as shear stress.¹³ The pathophysiology of hypertensive emergency remains incompletely understood, but an initial abrupt rise in vascular resistance seems to be a necessary initiating step (figure 1). Increased vasoreactivity can be precipitated by release of vasoconstricting substances such as angiotensin II or norepinephrine, or can occur as a result of relative hypovolaemia. Activation of the renin-angiotensin-aldosterone system seems to be important in the pathophysiology of severe hypertension. Experiments with transgenic animals have highlighted the importance of the renin-angiotensin system. Rats expressing the mouse renin gene, *Ren-2*, develop severe hypertension in comparison with controls.¹⁴ Moreover, rats that are double transgenic for the human renin and human angiotensinogen genes develop not only moderately severe hypertension but also an inflammatory vasculopathy similar to that seen in severe human hypertension.¹⁵ There is evidence that angiotensin II has direct cytotoxic effects on the vessel wall.^{16,17} Some of these effects seem to be mediated through activation of expression of genes for proinflammatory cytokines (such as interleukin 6) and activation of the transcription factor NF- κ B (nuclear factor κ B) by angiotensin II.^{16,17} Many of the vascular sequelae and much of the target-organ dysfunction seen in hypertensive emergencies may be due to the injurious effects of angiotensin II on the blood vessel wall. Moreover, inhibition of angiotensin-converting enzyme (ACE) prevents the development of malignant hypertension in transgenic rats expressing the murine renin gene.¹⁸

During an initial rise in blood pressure, the endothelium attempts to compensate for the change in vascular resistance through increased autocrine/paracrine release of vasodilator molecules such as nitric oxide. When

hypertension is sustained or severe, these compensatory endothelial vasodilator responses are overwhelmed, leading to endothelial decompensation, which promotes further rises in blood pressure and endothelial damage. Thus, a vicious cycle of homeostatic failure is initiated, with progressive increases in vascular resistance and further endothelial dysfunction. Although the exact cellular mechanisms leading to loss of endothelial function in hypertensive syndromes are poorly understood, putative mechanisms include proinflammatory responses induced by mechanical stretching, such as secretion of cytokines¹⁹ and monocyte chemoattractant protein 1,²⁰ increased endothelial-cell cytosolic calcium concentrations,²¹ release of the vasoconstrictor endothelin 1,²² and upregulated expression of endothelial adhesion molecules.²³ Increased expression of vascular cell adhesion molecules, such as P-selectin, E-selectin, or intracellular adhesion molecule 1, by endothelial cells promotes local inflammation leading to additive loss of endothelial function. Ultimately, these molecular events may trigger increases in endothelial permeability, inhibit local endothelial fibrinolytic activity, and activate the coagulation cascade. Platelet aggregation and degranulation on damaged endothelium may promote further inflammation, thrombosis, and vasoconstriction.

Clinical evaluation

The history and results of physical examination determine the nature, severity, and subsequent management of acute hypertensive syndromes. The history should include details of the duration and severity of pre-existing hypertension and the presence of previous end-organ damage, particularly renal and cerebrovascular disease. Details of antihypertensive drug therapy, degree of blood-pressure control, intake of over-the-counter preparations such as sympathomimetic agents, and use of illicit drugs such as cocaine should be ascertained promptly.²⁴ Also, the physician should assess whether specific symptoms suggesting end-organ compromise are present. These symptoms include chest pain (myocardial ischaemia or infarction, aortic dissection), back pain (aortic dissection), dyspnoea (pulmonary oedema or congestive heart failure), and neurological symptoms, seizures, or altered consciousness (hypertensive encephalopathy). The physical examination should assess whether end-organ damage is present. Blood pressure should be measured with the patient in both supine and standing positions (if possible) to assess whether there is volume depletion. The blood pressure should also be measured in both arms; a significant difference should raise the suspicion of aortic dissection. A fundoscopic examination is particularly useful because it can distinguish a true hypertensive emergency from a hypertensive urgency (the presence of new haemorrhages, exudates, or papilloedema indicating the former). The cardiovascular examination should focus on the presence of heart failure (raised jugular venous pressure, crackles, third heart sound, or gallop). The neurological examination should assess level of consciousness, signs of meningeal irritation, visual fields, and focal signs such as drift of the outstretched arms. Important immediate investigations include measurement of concentrations of urea, electrolytes, and serum creatinine, a full blood count (including a peripheral blood smear for evidence of haemolysis indicated by the presence of schistocytes), an electrocardiogram, chest radiography, and urine analysis. In some cases, measurement of plasma renin activity and aldosterone in samples of blood drawn at

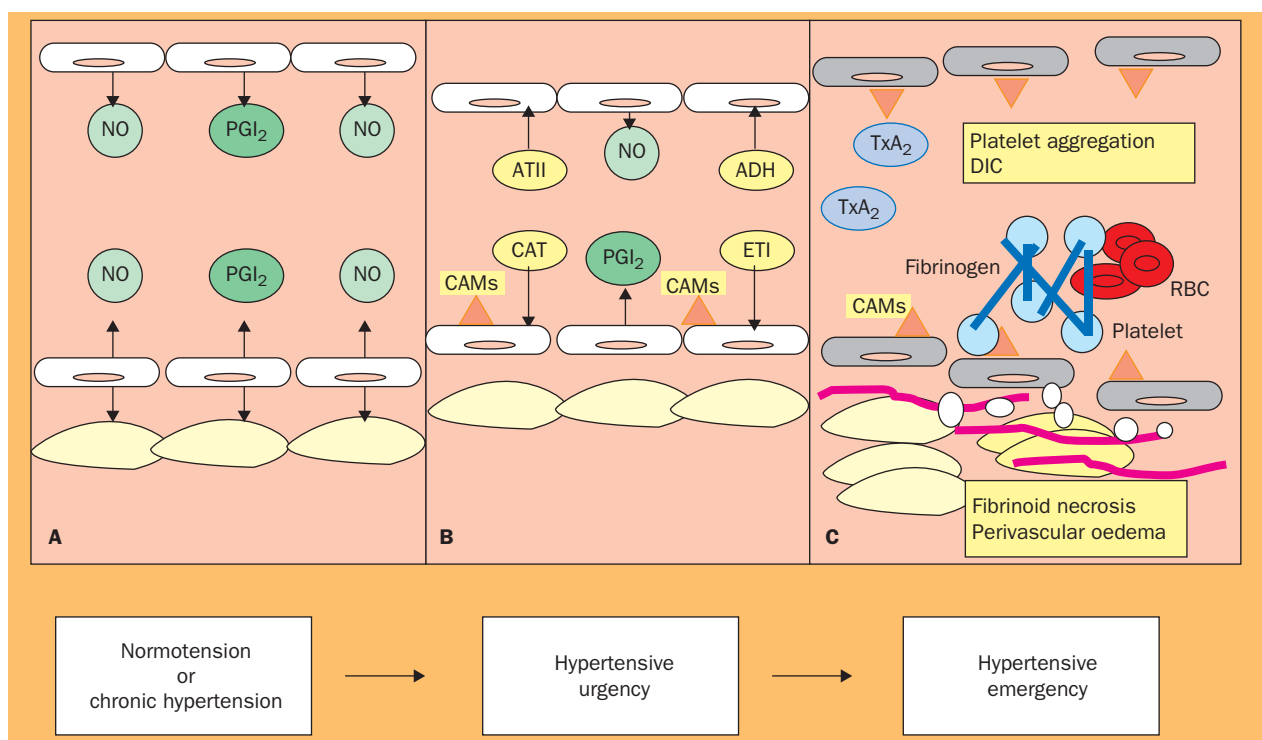


Figure 1: **Putative vascular pathophysiology of hypertensive emergencies**

A: the endothelium modulates vascular resistance through the autocrine/paracrine release of vasoactive molecules such as nitric oxide (NO) and prostacyclin (PGI₂). B: acute changes in vascular resistance occur in response to excess production of catecholamines, angiotensin II (ATII), vasopressin (ADH), aldosterone, thromboxane (TxA₂), and endothelin 1 (ET1), or low production of endogenous vasodilators such as NO and PGI₂. Acute or severe rises in blood pressure can also promote expression of cellular adhesion molecules (CAMs) by the endothelium. C: during a hypertensive emergency, endothelial control of vascular tone may be overwhelmed, leading to end-organ hyperperfusion, arteriolar fibrinoid necrosis, and increased endothelial permeability with perivascular oedema. Loss of endothelial fibrinolytic activity coupled with activation of coagulation and platelets promotes disseminated intravascular coagulation (DIC).

the time of initial assessment can be useful in making a retrospective diagnosis.

Hypertensive encephalopathy

Cerebral blood flow is autoregulated within specific limits. In normotensive individuals, cerebral blood flow remains unchanged between mean arterial pressures of 60 mm Hg and 120 mm Hg (figure 2). As mean arterial pressure increases, compensatory cerebral vasoconstriction limits cerebral hyperperfusion. At a mean arterial pressure of about 180 mm Hg this autoregulation is overwhelmed; cerebral vasodilation ensues and cerebral oedema develops. Previously normotensive individuals can develop signs of encephalopathy at blood pressures as low as 160/100 mm Hg, whereas individuals with long-standing hypertension may not do so until the blood pressure rises to 220/110 mm Hg or greater.

Hypertensive encephalopathy is defined as an acute organic brain syndrome (acute encephalopathy or delirium)

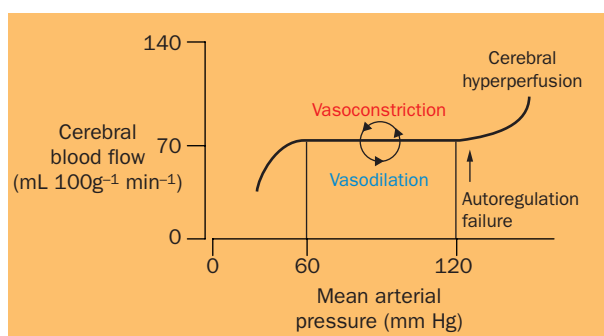


Figure 2: **Autoregulation of cerebral blood flow**

occurring as a result of failure of the upper limit of cerebral vascular autoregulation (autoregulation breakthrough). There may be differences between individuals in the degree of hypertension that can give rise to autoregulatory dysfunction leading to encephalopathy and differences within one person over time depending on comorbid factors. Clinically, hypertensive encephalopathy is characterised by the acute or subacute onset of lethargy, confusion, headache, visual disturbance (including blindness), and seizures. Encephalopathy can occur with or without proteinuria and hypertensive retinopathy. Seizures may be the presenting manifestation;²⁵ these may be focal or generalised, or focal with secondarily generalised tonic-clonic convulsions. If not adequately treated, hypertensive encephalopathy can progress to cerebral haemorrhage, coma, and death. It is associated with untreated or undertreated hypertension and other known causes and associations of severe hypertension such as renal disease, immunosuppressive therapy,^{26,27} erythropoietin use,²⁸ and thrombotic thrombocytopenic purpura;²⁹ it may also occur in unique circumstances such as in pre-eclampsia and eclampsia.³⁰ In thrombotic thrombocytopenic purpura, and in the syndrome of haemolysis, raised liver enzymes, and low platelet count associated with pre-eclampsia and eclampsia,³¹ thrombocytopenia can predispose to intracerebral haemorrhage.

The pathogenesis of hypertensive encephalopathy is incompletely understood, although it seems to be related to hypertensive cerebrovascular endothelial dysfunction, disruption of the blood-brain barrier with increased permeability, cerebral oedema, and microhaemorrhage formation. In parallel with the clinical presentation,

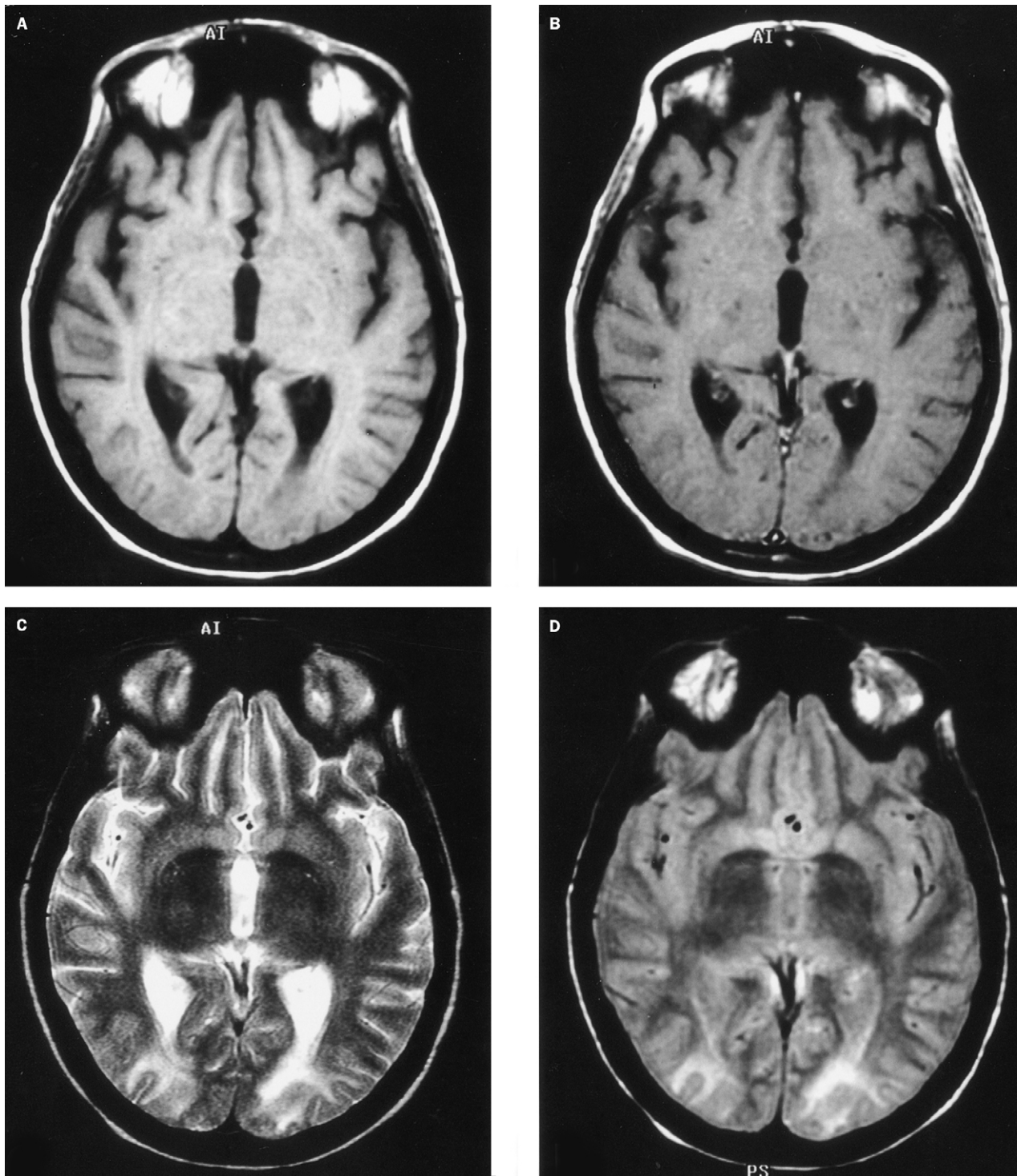


Figure 3: Axial magnetic resonance images of a patient with hypertensive encephalopathy

A,B: T₁-weighted images, before and after gadolinium; no remarkable features are present. C,D: T₂-weighted (C) and proton-density (D) images show occipital hyperintensity consistent with posterior leucoencephalopathy. Reproduced with permission from reference 28.

magnetic resonance neuroimaging shows a characteristic posterior leucoencephalopathy that predominantly (but not exclusively) affects the white matter of the parieto-occipital regions (figure 3).³² These changes are best appreciated on T₂-weighted images; they commonly involve other posterior structures such as the cerebellum and brainstem, in occasional cases the cortex is involved, and also in occasional cases there is more anterior involvement in the temporal and frontal regions. Although the imaging

changes are bilateral in most cases, they can be asymmetrical. Posterior cerebral changes can also be seen on computed tomography scanning in some patients. Studies with diffusion-weighted magnetic resonance imaging show that the leucoencephalopathy is primarily due to vasogenic rather than cytotoxic oedema.³³ In one patient, magnetic resonance spectroscopy showed a lower than normal ratio of N-acetyl-aspartate to creatine in the occipital region, indicating neuronal dysfunction.³⁴ The

| End organ | Complications | Therapeutic considerations |
|-----------|--|---|
| Aorta | Aortic dissection | β -blockade, labetalol (decrease dp/dt), sodium nitroprusside with β -blockade, avoid isolated use of pure vasodilators |
| Brain | Hypertensive encephalopathy | Avoid centrally acting antihypertensive drugs such as clonidine |
| | Cerebral infarction or haemorrhage | Avoid centrally acting agents; avoid rapid decreases in blood pressure |
| Heart | Myocardial ischaemia | Intravenous glyceryl trinitrate, β -blockade |
| | Myocardial infarction Heart failure | Diuretics and ACE inhibitors useful, β -blockers with caution |
| Kidney | Renal insufficiency | Diuretics with caution, calcium antagonists useful |
| Placenta | Eclampsia | Hydralazine, labetalol, calcium antagonists useful; avoid sodium nitroprusside |

dp/dt=change in pressure/change in time.

Table 1: **End-organ complications of hypertensive emergencies**

reason for the anatomical predilection to the parieto-occipital areas is unclear, although a possible mechanism is a relative paucity of vascular sympathetic (and thus protective) innervation of the vessels of the posterior circulation arising from the basilar artery.³⁵ Hypertensive encephalopathy predominantly affecting the brainstem has also been reported.³⁶ In parallel with the imaging findings, the electroencephalogram can show loss of the posterior dominant alpha rhythm, generalised slowing, and posterior epileptiform discharges, which resolve after clinical improvement.^{27,29,30}

Hypertensive encephalopathy and its clinical and neuroimaging consequences are potentially fully reversible with timely and appropriate management; thus the term hypertensive reversible posterior leucoencephalopathy syndrome (PLS) has become popular.²⁶ This syndrome, diagnosed clinicoradiologically, is found in both adults and children; it has both hypertensive and non-hypertensive causes. Non-hypertensive causes and associations of PLS include immunosuppressive and cytotoxic therapy (cyclosporin, tacrolimus, cisplatin)^{27,37,38} interferon- α ,²⁶ AIDS,³⁹ thrombotic thrombocytopenic purpura,²⁹ blood transfusion,⁴⁰ and carotid endarterectomy hyperperfusion syndrome.⁴¹ However, some of the patients reported in these settings (eg, some of those treated with cyclosporin and tacrolimus) also had acutely raised blood pressure.^{26,27} The causes of PLS (and its underlying endothelial disturbance) are probably multifactorial—for example, cyclosporin neurotoxicity and hypertension occurring after renal transplantation, and in patients with thrombotic thrombocytopenic purpura, acute renal failure, and associated hypertension.²⁹

Management

General principles

There have been no large clinical trials investigating optimum therapy in patients presenting with hypertensive emergencies. Such studies would be difficult to design and would be complicated by heterogeneity of patients and diseases. Therefore, therapy is not evidence based and in general has been dictated by consensus.^{1,42} Management of patients with acute hypertensive syndromes should be tailored to the individual patient and based not only on the absolute value of blood pressure, but on the presence or absence of end-organ damage (or the imminent threat of such damage). Hypertensive urgencies can be treated with oral antihypertensive agents such as ACE inhibitors, calcium-channel antagonists, β -blockers, α -blockers, or a combination of such drugs. After a period of monitoring, the patient can safely be discharged with close outpatient

follow-up and adjustment of therapy. Ideally, these patients should be seen within 1–2 days of initial presentation.

A patient presenting with a hypertensive emergency should be admitted to an intensive-care unit, and an arterial line should be placed for accurate monitoring of blood pressure. However, therapy should not be delayed while such measures are being instituted. Intravenous administration of antihypertensive drugs is generally preferred in this situation. Patients may present with evidence of compromise of one or more end organs. Different antihypertensive therapeutic strategies may be advantageous with particular end-organ syndromes (table 1). In general, most extracerebral end-organ dysfunction benefits from rapid lowering of blood pressure. The recommended aims are reduction of mean arterial pressure by no more than 20–25% within a period of minutes to 2 h or a decrease in diastolic blood pressure to 100–110 mm Hg over minutes to hours.⁴² More rapid reduction in blood pressure is to be avoided, because it can worsen end-organ function.

Specific drug therapy

The aim of drug therapy in patients with hypertensive emergencies is to reduce blood pressure in a controlled, predictable, and safe way. Various parenteral drugs are suitable (table 2). Depending on the nature of target-organ damage, a particular drug or therapeutic strategy may be more or less appropriate. Sodium nitroprusside can be used safely in many instances.⁴² It is a short-acting arterial and venous dilator and should be given only by continuous intravenous infusion with simultaneous intra-arterial blood-pressure monitoring. Its use may be complicated by the occurrence of hypotension, which is rapidly reversible when the infusion is discontinued. Other complications include cyanate or thiocyanate toxicity when this drug is given for a long period (days), especially in patients with hepatic or renal dysfunction. Although sodium nitroprusside has been reported to increase intracranial pressure,⁴³ the contemporaneous fall in systemic vascular resistance seems to offset this effect. Sodium nitroprusside is generally recommended as therapy for hypertensive emergencies including hypertensive encephalopathy.⁴² Other drugs that are useful in most instances include intravenous labetalol,⁴⁴ which has both α -blocking and β -blocking activity, and intravenous calcium-channel antagonists. The β -blocking effect of labetalol is about a fifth that of propranolol. Adverse effects include nausea, vomiting, and flushing. Bradycardia, heart block, bronchospasm, and heart failure can also complicate its use.

| Drug | Dose | Onset | Duration | Adverse effects |
|-----------------------|--|-----------|-----------|---|
| Sodium nitroprusside* | 0.25–10 $\mu\text{g kg}^{-1} \text{min}^{-1}$ | Immediate | 1–2 min | Hypotension, nausea, vomiting, cyanate toxicity |
| Labetalol | 20–80 mg bolus (every 10 min) 2 mg/min infusion | 5–10 min | 2–6 h | Nausea, vomiting, heart block, bronchospasm |
| Hydralazine | 10–20 mg bolus | 10 min | 2–6 h | Reflex tachycardia |
| Fenoldopam | 0.1–0.6 $\mu\text{g kg}^{-1} \text{min}^{-1}$ | 5–10 min | 10–15 min | Hypotension, headache |
| Glyceryl trinitrate | 5–100 $\mu\text{g/min}$ | 1–3 min | 5–15 min | Headache, vomiting |
| Enalaprilat | 1.25–5.00 mg bolus | 15 min | 4–6 h | Hypotension, renal failure |
| Nicardipine | 2–10 mg/h | 5–10 min | 2–4 h | Reflex tachycardia, flushing |
| Phentolamine | 5–10 mg/min | 1–2 min | 3–5 min | Reflex tachycardia |

*Risk of toxic effects in patients with renal impairment.

Table 2: **Commonly used parenteral antihypertensive drugs**

Fenoldopam mesylate has been approved for treatment of hypertensive emergencies.^{45,46} It is a peripheral dopamine-1-receptor agonist; its antihypertensive actions are due to a combination of direct vasodilation and renal-arterial dilation and natriuresis. Reported side-effects of fenoldopam include headache, flushing, and increased intraocular pressure.⁴⁵ Fenoldopam and nitroprusside are equally effective in the treatment of severe hypertension.⁴⁷

ACE inhibitors and hydralazine are also valuable in some patients.⁴⁸ In the acute setting, however, ACE inhibitors should be used cautiously, because these drugs can lead to precipitous falls in blood pressure in patients who are hypovolaemic or in those with underlying renal-artery stenosis. ACE-inhibitor therapy is thus contraindicated in patients with renal-artery stenosis. Diuretics should generally be avoided in hypertensive emergencies unless there is evidence of left-ventricular failure and pulmonary oedema, because many patients have, or develop, hypovolaemia during such emergencies possibly as a result of pressure-induced natriuresis.⁴⁹ Moreover, fluid replacement has been reported to lower blood pressure and improve renal function in certain patients with severe hypertension and evidence of hypovolaemia.⁵⁰

Specific settings

The management of hypertensive encephalopathy includes early recognition, withdrawal of exacerbating factors (eg, erythropoietin), individualised antihypertensive drug treatment as for other hypertensive emergencies, and appropriate (and short-term in most cases) parenteral anticonvulsant treatment with phenytoin or fosphenytoin, benzodiazepines, or barbiturates, or a combination.²⁵ Although not evidence based, the use of anticonvulsants in patients with hypertensive encephalopathy who are having seizures is reasonable and will itself help to lower blood pressure. In patients presenting with hypertensive encephalopathy, the aim should be a lowering of mean arterial pressure by about 20% or to a diastolic blood pressure of 100 mm Hg, whichever value is greater, within the first hour. Particular caution is necessary in elderly patients and in those with pre-existing hypertension in whom overaggressive reduction in blood pressure may be accompanied by worsening neurological status and even stroke. In these circumstances, infusion of antihypertensive drugs should be discontinued or the dose lowered. Suitable agents in the management of hypertensive encephalopathy include sodium nitroprusside, labetalol, enalapril, and hydralazine. Clonidine should be avoided because it is a central-nervous-system depressant. Patients with high blood pressure and other risk factors for posterior leucoencephalopathy such as immunosuppressive therapy or thrombotic thrombocytopenic purpura should be vigorously and carefully treated, because they can develop posterior autoregulatory failure at blood pressures lower than those classically associated with florid hypertensive encephalopathy.

The use of antihypertensive therapy in cerebral ischaemic syndromes, in contrast to hypertensive encephalopathy, is controversial. In many patients with acute ischaemic stroke, blood pressure is raised; in addition, cerebral autoregulation may fail after a stroke, particularly within the infarct area and in the surrounding ischaemic penumbra, so this area becomes even more prone to hypoperfusion during blood-pressure reduction. Moreover, there is evidence of a better outcome in patients with acute stroke who have higher blood pressures. For these reasons, antihypertensive therapy

is not routinely recommended for patients with stroke and hypertension. Current studies are attempting to address the optimum management of blood pressure in acute stroke. In patients with intracerebral or subarachnoid haemorrhage and severely raised blood pressure (diastolic blood pressure >130 mm Hg), there may be benefit with careful and gradual reduction of blood pressure.

In addition to delivery of the baby and placenta, parenteral magnesium is the treatment of choice to prevent the evolution of pre-eclampsia to eclampsia (seizures and worsening encephalopathy).⁵¹ There is also long-standing experience with several suitable antihypertensive drugs. The parenteral antihypertensive drugs most commonly used during pregnancy are hydralazine and labetalol. Hydralazine can lead to a reflex tachycardia that may require concomitant β -blockade. ACE inhibitors and angiotensin-receptor antagonists are contraindicated in pregnancy.

Myocardial ischaemia in the absence of obstructive coronary atherosclerosis can be precipitated by severe rises in blood pressure through increased left-ventricular wall stress and myocardial oxygen demand. Intravenous nitrates are very useful in this situation; nitrates improve coronary perfusion, decrease left-ventricular preload, and have moderate hypotensive action. Intravenous β -blockers are also useful through a simultaneous reduction in both heart rate and blood pressure. Pure vasodilators should be avoided in the presence of myocardial ischaemia because they tend to cause a reflex sympathetic tachycardia that may itself increase myocardial oxygen demand.

The presence of left-ventricular failure necessitates a rapid reduction in blood pressure. Intravenous glyceryl trinitrate or sodium nitroprusside is useful and the dose should be titrated until blood pressure is controlled and signs of heart failure have been alleviated. These drugs can be used in combination with loop diuretics.

Aortic dissection is the most dramatic and most rapidly fatal complication of severe hypertension. Mortality rates from aortic dissection remain high.⁵² Systolic blood pressure should be decreased as rapidly as possible to 100–110 mm Hg or lower. This reduction is best achieved with a combination of β -blockers (or labetalol) and intravenous vasodilators such as sodium nitroprusside. Therapy for acute aortic dissection aims to reduce stress on the aortic wall by lowering both blood pressure and heart rate and consequently the dp/dt (change in blood pressure/change in time). Because sodium nitroprusside can cause reflex tachycardia, therapy with β -blocking agents should be started beforehand.

Renal insufficiency can be a cause or a consequence of hypertensive emergency. Patients on haemodialysis and particularly those receiving erythropoietin therapy commonly present with severely raised blood pressure. Hypertensive emergencies are common in patients with renal transplants, especially those receiving cyclosporin and corticosteroids. The primary goal in the management of new-onset renal insufficiency accompanying severe hypertension is to limit further renal damage through blood-pressure control. Antihypertensive drugs that preserve renal blood flow, such as calcium antagonists and α -adrenergic blocking agents are appropriate. If hypertension remains severe or refractory, other vasodilators such as sodium nitroprusside, fenoldopam or hydralazine can be used. Diuretic use in patients with severe hypertension and renal failure may be beneficial or deleterious, depending on the patient's volume status, and this feature should be carefully considered before initiation of such therapy.

CJV is supported by the American College of Cardiology/Merck Adult Cardiology Research Fellowship Grant.

References

- 1 Joint National Committee on Prevention, Detection, Evaluation, and Treatment of High Blood Pressure. Sixth Report. *Arch Intern Med* 1997; **157**: 2413–46.
- 2 He J, Whelton PK. Epidemiology and prevention of hypertension. *Med Clin N Am* 1997; **81**: 1077–97.
- 3 Cooper R, Rotini C. Hypertension in blacks. *Am J Hypertens* 1997; **7**: 804–12.
- 4 Guidelines Subcommittee. 1999 WHO–International Society of Hypertension Guidelines for the Management of Hypertension. *J Hypertens* 1999; **17**: 151–83.
- 5 Ramsay LE, Williams B, Johnston DG, et al. Guidelines for the management of hypertension: report of the third working party of the British Hypertension Society, 1999. *J Hum Hypertens* 1999; **13**: 569–92.
- 6 Bennett NM, Shea S. Hypertensive emergency: case criteria, sociodemographic profile, and previous care of 100 cases. *Am J Public Health* 1988; **78**: 636–40.
- 7 Mosterd A, D'Agostino RB, Silbershatz H, et al. Trends in the prevalence of hypertension, antihypertensive therapy, and left ventricular hypertrophy from 1950 to 1989. *N Engl J Med* 1999; **340**: 1221–27.
- 8 Berlowitz DR, Ash AS, Hickey EC, et al. Inadequate management of blood pressure in a hypertensive population. *N Engl J Med* 1998; **339**: 1957–63.
- 9 Mancia G, Sega R, Milesi V, Cesana G, Zanchetti A. Blood-pressure control in the hypertensive population. *Lancet* 1997; **349**: 454–57.
- 10 Meissner I, Whisnart JP, Sheps SG, et al. Detection and control of high blood pressure in the community. Do we need a wake-up call? *Hypertension* 1999; **34**: 466–71.
- 11 Finnerty FA. Hypertensive encephalopathy. *Am J Med* 1972; **52**: 672–78.
- 12 Furchgott RF, Zawadzky JV. The obligatory role of endothelial cells in the relaxation of arterial smooth muscle by acetylcholine. *Nature* 1980; **288**: 373–76.
- 13 Kuchan MJ, Jo H, Frangos JA. Role of G proteins in shear stress-mediated nitric oxide production by endothelial cells. *Am J Physiol* 1994; **267**: C753–58.
- 14 Mullins JJ, Peters J, Ganten D. Fulminant hypertension in transgenic rats harbouring the mouse *Ren-2* gene. *Nature* 1990; **344**: 541–44.
- 15 Ganten D, Wagner J, Zeh K, et al. Species specificity of renin kinetics in transgenic rats harboring the human renin and angiotensinogen genes. *Proc Natl Acad Sci USA* 1992; **89**: 7806–10.
- 16 Funakoshi Y, Ichiki T, Ito K, Takeshita A. Induction of interleukin-6 expression by angiotensin II in rat vascular smooth muscle cells. *Hypertension* 1999; **34**: 118–25.
- 17 Muller DN, Dechend R, Mervaala EM, et al. NF- κ B inhibition ameliorates angiotensin II-induced inflammatory damage in rats. *Hypertension* 2000; **35**: 193–201.
- 18 Montgomery HE, Kiernan LA, Whitworth CE, et al. Inhibition of tissue angiotensin converting enzyme activity prevents malignant hypertension in TGR (mREN2)27. *J Hypertens* 1998; **16**: 635–43.
- 19 Okada M, Matsumori A, Ono K, et al. Cyclic stretch upregulates production of interleukin-8 and monocyte chemoattractant and activating factor/monocyte chemoattractant protein-1 in human endothelial cells. *Arterioscler Thromb Vasc Biol* 1998; **18**: 894–901.
- 20 Wung BS, Cheng JJ, Chao YJ, Lin J, Shyy YJ, Wang DL. Cyclic strain increases monocyte chemoattractant protein-1 secretion in human endothelial cells. *Am J Physiol* 1996; **270**: H1462–68.
- 21 Touyz RM, Milne FJ. Alterations in intracellular cations and cell membrane ATPase activity in patients with malignant hypertension. *J Hypertens* 1995; **13**: 867–74.
- 22 MacArthur H, Warner TD, Wood EG, Corder R, Vane JR. Endothelin-1 release from endothelial cells in culture is elevated both acutely and chronically by short periods of mechanical stretch. *Biochem Biophys Res Commun* 1994; **200**: 395–400.
- 23 Verhaar MC, Beutler JJ, Gaillard CA, Koomans HA, Fijnheer R, Rabelink TJ. Progressive vascular damage in hypertension is associated with increased levels of circulating P-selectin. *J Hypertens* 1998; **16**: 45–50.
- 24 Grossman E, Messerli FH. High blood pressure. A side effect of drugs, poisons, and food. *Arch Intern Med* 1995; **155**: 450–60.
- 25 Delanty N, Vaughan CJ, French JA. Medical causes of seizures. *Lancet* 1998; **352**: 383–90.
- 26 Hinchey J, Chaves C, Appignani B, et al. A reversible posterior leukoencephalopathy syndrome. *N Engl J Med* 1996; **334**: 494–500.
- 27 Torocsik HV, Curless RG, Post J, Tzakis AG, Pearse L. FK506-induced leukoencephalopathy in children with organ transplants. *Neurology* 1999; **52**: 1497–500.
- 28 Delanty N, Vaughan C, Frucht S, Stubgen P. Erythropoietin-associated hypertensive posterior leukoencephalopathy. *Neurology* 1997; **49**: 686–89.
- 29 Bakshi R, Shaikh ZA, Bates VE, Kinkel PR. Thrombotic thrombocytopenic purpura: brain CT and MRI findings in 12 patients. *Neurology* 1999; **52**: 1285–88.
- 30 Manfredi M, Beltramello A, Bongiovanni LG, Polo A, Pistoia L, Rizzuto N. Eclamptic encephalopathy: imaging and pathogenetic considerations. *Acta Neurol Scand* 1997; **96**: 277–82.
- 31 Feske SK, Sperling RA, Schwartz RB. Extensive reversible brain magnetic resonance lesions in a patient with HELLP syndrome. *J Neuroimaging* 1997; **7**: 247–50.
- 32 Schwartz RB, Jones KM, Kalina P, et al. Hypertensive encephalopathy: findings on CT, MR imaging and SPECT imaging in 14 cases. *AJR Am J Roentgenol* 1992; **159**: 379–83.
- 33 Schwartz RB, Mulkern RV, Gudbjartsson H, Jolesz F. Diffusion-weighted MR imaging in hypertensive encephalopathy: clues to pathogenesis. *AJNR Am J Neuroradiol* 1998; **19**: 859–62.
- 34 Pavlakis SG, Frank Y, Kalina P, et al. Occipital-parietal encephalopathy: a new name for an old syndrome. *Pediatr Neurol* 1997; **16**: 145–48.
- 35 Beausang-Linder M, Bill A. Cerebral circulation in acute arterial hypertension: protective effects of sympathetic nervous activity. *Acta Physiol Scand* 1981; **111**: 193–99.
- 36 Wang MC, Escott EJ, Breeze RE. Posterior fossa swelling and hydrocephalus resulting from hypertensive encephalopathy: case report and review of the literature. *Neurosurgery* 1999; **44**: 1325–27.
- 37 Gleeson JG, duPlessis AJ, Barnes PD, Rivello Jr JJ. Cyclosporin A acute encephalopathy and seizure syndrome in childhood: clinical features and risk of seizure recurrence. *J Child Neurol* 1998; **13**: 336–44.
- 38 Ito Y, Arahata Y, Goto Y, et al. Cisplatin neurotoxicity presenting as reversible posterior leukoencephalopathy syndrome. *AJNR Am J Neuroradiol* 1998; **19**: 415–17.
- 39 Frank Y, Pavlakis S, Black K, Bakshi S. Reversible occipital-parietal encephalopathy syndrome in an HIV-infected child. *Neurology* 1998; **51**: 915–16.
- 40 Ito Y, Niwa H, Iida T, Nagamatsu M, Yasuda T, Yanagi T, Sobue G. Post-transfusion reversible posterior leukoencephalopathy syndrome with cerebral vasoconstriction. *Neurology* 1997; **49**: 1174–75.
- 41 Baptista MV, Maeder P, Dewarrat A, Bogousslavsky J. Conflicting images. *Lancet* 1998; **351**: 414.
- 42 Calhoun DA, Oparil S. Treatment of hypertensive crises. *N Engl J Med* 1990; **323**: 1177–83.
- 43 Cottrell JE, Patel K, Turndorf H, Ransohoff J. Intracranial pressure changes induced by sodium nitroprusside in patients with intracranial mass lesions. *J Neurosurg* 1978; **48**: 329–31.
- 44 Wilson DJ, Wallin JD, Vlachakis ND. Intravenous labetalol in the treatment of severe hypertension and hypertensive emergencies. *Am J Med* 1983; **75** (suppl): 95–102.
- 45 Shusterman NH, Elliott WJ, White WB. Fenoldopam, but not nitroprusside, improves renal function in severely hypertensive patients with impaired renal function. *Am J Med* 1993; **95**: 161–68.
- 46 Oparil S, Aronson S, Deeb GM, et al. Fenoldopam: a new parenteral antihypertensive: consensus roundtable on the management of perioperative hypertension and hypertensive crises. *Am J Hypertens* 1999; **12**: 653–64.
- 47 Pilmer BL, Green JA, Panacek EA, et al. Fenoldopam mesylate versus sodium nitroprusside in the acute management of severe systemic hypertension. *J Clin Pharmacol* 1993; **33**: 549–53.
- 48 Hirschl MM, Binder M, Bur A, et al. Clinical evaluation of different doses of intravenous enalaprilat in patients with hypertensive crises. *Arch Intern Med* 1995; **155**: 2217–23.
- 49 Orth H, Ritz E. Sodium depletion in accelerated hypertension. *N Engl J Med* 1975; **292**: 1133.
- 50 Houston MC. Pathophysiology, clinical aspects, and treatment of hypertensive crises. *Prog Cardiovasc Dis* 1989; **32**: 99–148.
- 51 Lucas MJ, Leveno KJ, Cunningham FG. A comparison of magnesium sulfate with phenytoin for the prevention of eclampsia. *N Engl J Med* 1995; **333**: 201–05.
- 52 Pretre R, Von Segesser LK. Aortic dissection. *Lancet* 1997; **349**: 1461–64.

A list of further reading appears on *The Lancet's* website www.thelancet.com